

University of Dundee

# The Hall Technique

A minimal intervention, child centred approach to managing the carious primary molar



## A Users Manual

Copyright Dafydd Evans & Nicola Innes  
Illustrations copyright Dafydd Evans & Amy McKay

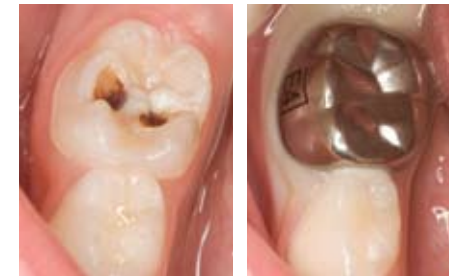# Contents

2	<b>Introduction</b>
3	<b>Background to the Hall Technique</b>
3	How did the Hall Technique come about?
3	How does the Hall Technique relate to conventional crowns for primary molars?
4	How does the Hall Technique get around some of these difficulties?
7	What about the soft dentinal lesion?
8	How does the pulp react to caries?
8	Summary
10	<b>Evidence behind the Hall Technique</b>
10	Is the Hall Tecchnique effective
10	Clinical outcomes
11	And is the Hall Technique acceptable to children, their parent and dentists?
12	Summary of evidence for the Hall Technique
13	<b>Case selection; Using the Hall Technique in clinical practice</b>
13	<b>Stage 1.</b> Treatment planning for Hall crowns, and some important information
17	When can Hall crowns be a suitable management option for carious primary molars?
18	When is there no need to fit Hall crowns?
18	Summary of indications and contra-indications for the Hall Technique
19	<b>Fitting Hall crowns; A Practical Guide</b>
20	The appointment for fitting the crown
21	Instruments to have ready
22	<b>Fitting a Hall ccrown</b>
23	<b>Step 1 of 7:</b> Assessing the tooth shape, contact points/areas and the occlusion
27	<b>Step 2 of 7:</b> Protecting the airway
28	<b>Step 3 of 7:</b> Sizing a crown
29	<b>Step 4 of 7:</b> Loading the crown with cement
29	<b>Step 5 of 7:</b> Fitting the crown, and first stage seating
31	<b>Step 6 of 7:</b> Wipe the excess cement away, check fit and second stage seating
32	<b>Step 7 of 7:</b> Final clearance of cement, check occlusion and discharge
37	<b>Bibliography and further information</b>
37	“Sealing in” caries
37	The Hall Technique
36	Final Note

# Introduction

The Hall Technique is a method for managing carious primary molars where decay is sealed under preformed metal crowns (PMCs) without local anaesthesia, tooth preparation or any caries removal.

**Figure 1.** Provision of a preformed metal crown for a mandibular second primary molar (85) using the Hall Technique; before, and immediately after the crown being fitted.



Clinical trials have shown the Hall Technique to be effective, and acceptable to the majority of children, their parents and clinicians. It is NOT, however, an easy, quick fix solution to the problem of the carious primary molar. Like all clinical interventions, for success the Hall Technique requires careful and appropriate case selection, a high level of clinical skill, excellent patient management and long term monitoring. In addition, it must always be provided with a full and effective caries preventive programme (see SIGN Guideline 83, downloadable from [www.sign.ac.uk](http://www.sign.ac.uk))

#### This manual provides information on:

- the background to the Hall Technique;
- the evidence behind the Hall Technique;
- information on case selection; and
- a “how to” guide on using the Hall Technique.

The Hall Technique will not suit every tooth, every child or every clinician. It can, however, be a useful and effective method of managing carious primary molars. This manual is intended as a guide to developing some skills in the application of the technique.

# Background to the Hall Technique

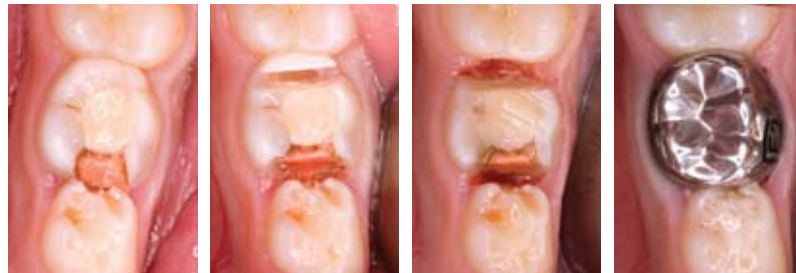## How did the Technique come about?

The technique is named after Dr Norna Hall, a general dental practitioner from Scotland, who developed and used the technique for over 15 years until she retired in 2006. A retrospective analysis of the outcomes for the teeth she treated in this way was published in the British Dental Journal in 2006 (see bibliography). This showed the technique to have outcomes comparable to conventional restorative techniques and led us to investigate it further through a randomised control trial (detailed later).

## How does the Hall Technique relate to conventional crowns for primary molars?

Preformed metal crowns (PMCs), sometimes referred to as stainless steel or nickel chrome crowns, have been used for restoring primary molars since 1950, and have become the accepted restoration of choice for the primary molar with caries affecting more than one surface, with a proven success rate as a restoration. Although popular with specialists, many clinicians find PMCs difficult to fit using the conventional approach, which requires the use of local anaesthetic injections and extensive tooth preparation (see Figure 2). There is also a high risk of damaging the adjacent first permanent molar when preparing a second primary molar for a PMC. For these, and other reasons, PMCs are not widely used in the UK, forming less than 1% of all restorations provided for children.

**Figure 2.**  
Preparation of a mandibular second primary molar (75) for a conventional PMC.



## How does the Hall Technique get around some of these difficulties?

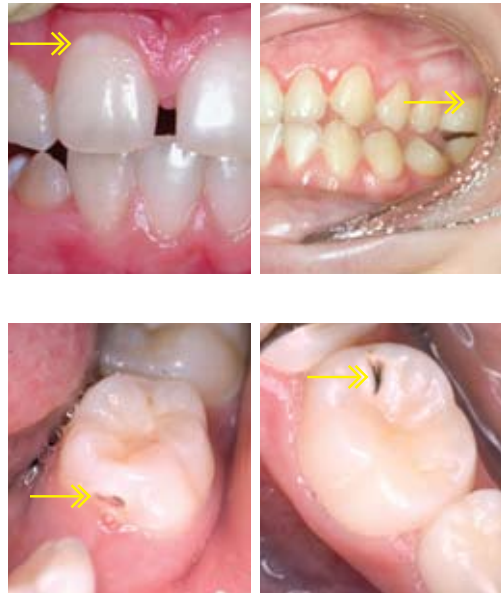With the Hall Technique, the process of fitting the crown is quick and non-invasive. The crown is seated over the tooth with no caries removal or tooth preparation of any kind, and local anaesthesia is not required.

## For decades, conventional teaching has been that all carious tooth tissue should be removed before restoring the tooth; how can leaving caries in the tooth be acceptable?

To answer this, it is worth firstly reviewing how and where caries begins. For many years it was assumed that the combination of a tooth surface, plaque and sugar would inevitably, after time, result in dental caries. However, despite the universal presence of plaque in the mouth and sugar in the diet, Clinicians will be aware that, except in extreme cases, the majority of tooth surfaces are relatively immune from caries, despite many of these surfaces usually being plaque stagnation areas.

Instead, clinically, 99% of dental caries begins on just two sites, which make up less than 1% of a tooth's surface; the base of fissures, and below the contact point of proximal surfaces.

**Figure 3.**  
The varying susceptibility of tooth surfaces to dental caries, despite the almost universal presence of plaque.



Low caries susceptibility

High caries susceptibility

What differs between these sites is the degree of shelter they offer to the plaque biofilm. The caries susceptible sites of fissures and the area below contact points provides plaque biofilm with sheltered microniches, allowing it the time and protection to mature to the level where the acidogenic bacteria (which are present in all plaque, but usually as a relatively low proportion) come to dominate the biofilm. As these acidogenic bacteria dominate the biofilm, the pH drops, eventually falling below the critical pH 5.5, at which hydroxyapatite becomes soluble, and the carious process begins. Once caries has caused cavitation of the enamel, the availability of sheltered surfaces suitable for plaque colonisation and maturation dramatically increases, and so the caries continues through the tooth. In summary, all plaque is potentially cariogenic, but needs a sheltered micro-niche for it to become actively cariogenic.

**This points to the community of micro-organisms within plaque being extremely sensitive and responsive to changes in its environment. For cariogenic plaque, if the environment can be altered to be unfavourable for the cariogenic bacteria within the community, plaque can lose its cariogenic potential.**

Plaque is far from the bland, homogenous material it appears to the naked eye. Given time, and a stable environment, plaque will mature into a complex, organised structure, with channels and pores. Its bacterial population will shift and change in composition, with symbiotic relationships developing between some species, while other species will be gradually squeezed out by their neighbours. In the deeper layers, organic acids formed as a by-product of bacterial metabolism, will favour a shift in the bacterial composition from non-cariogenic species such as *Streptococcus oralis* and *Streptococcus salivarius* to more cariogenic species such as the mutans streptococci and lactobacilli. Plaque has been described by Marsh as a “city of slime”. This is a useful analogy because just as a city is a complex structure, whose smooth functioning can be interrupted by a change in the supply of any number of factors (food, water, oxygen, power, light), so can the cariogenic potential of plaque be altered by changing the supply of carbohydrates, oxygen, or pH.

**Figure 4.**  
The plaque biofilm as a “City of slime” (after Marsh)



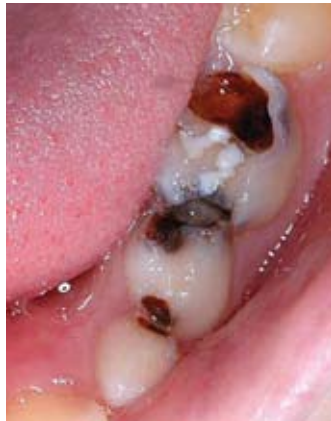DE, with apologies to “The Fantastic Voyage”

The Hall Technique manipulates the plaque’s environment by sealing it into the tooth, separating it from the substrates (essentially, nutrition) it would normally receive from the oral environment. There is a possibility that the plaque may continue to receive some nutrition from perfusion through the dentinal tubules. However, there is good evidence that if caries is effectively sealed from the oral environment, the bacterial profile in the caries changes significantly to a less cariogenic community, and the lesion does not progress.

## What about the soft dentinal lesion?

It is easy to see how an enamel lesion can be reversed but it can be difficult to imagine how we can influence a change in the soft dentinal lesion. However, most clinicians will be familiar with this clinical picture. Perhaps because the cavity has become self cleansing, or the child's diet has changed, the caries has arrested, with the colour changing to dark brown or black. This lesion was once soft and active, but is now hard and arrested. The evidence that caries can arrest is visible to us on a daily basis, yet we continue to provide management therapies (conventional restorative treatment) based on its complete excision.

**Figure 5.**  
Arrested caries on primary molars - the caries is dark and feels hard

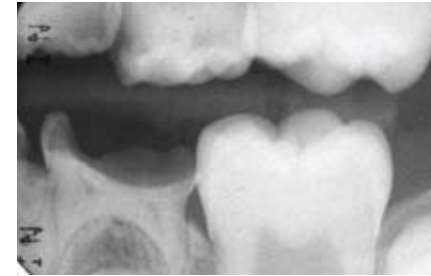

There is a Cochrane systematic review summarising the clinical evidence around sealing caries into teeth (see Bibliography).

## How does the pulp react to caries?

Just as it is becoming increasingly clear that dental caries is a dynamic process, it is also being recognised that the dentine/ pulp complex is far from passive when exposed to dental caries. Instead, these tissues mount an active defence response from the earliest stages of carious lesion formation in the enamel. Following a response from the immune system, odontoblasts are stimulated to lay down a layer of reactive dentine in an effort to distance the pulp from the approaching carious lesion, an effect readily observed, at a gross level, on radiographs.

**Figure 6.**  
The dental pulp of a primary molar responding to dentinal caries by the deposition of reactionary dentine



Clearly, the dental pulp of primary molars has the ability to maintain vitality and mount a defence response to dental caries, even when the dentine is involved. It is possible that the reparative potential of the primary tooth dental pulp has been underestimated.

### Summary

Most plaque is not actively cariogenic. Plaque which has matured in a sheltered environment to achieve cariogenic potential can lose that potential if its environment is altered. The bacteria within the community respond to the environment and in an unfavourable environment, cariogenic bacteria will not continue to flourish. Effective sealing from the oral environment can cause the necessary environmental change, resulting in plaque losing its cariogenic potential for as long as the seal is maintained. The Hall Technique is one method of achieving that seal for primary molar teeth.



# Evidence behind the Hall Technique

## Is the Hall Technique effective?

To answer this question, a clinical trial set in nine general dental practices in Tayside, Scotland looked at outcomes at two years for teeth where a Hall crown was fitted, compared to teeth which had undergone conventional restorative treatment.

The trial was a split mouth randomised control design, so teeth were matched on each side of the arch for type of lesion and extent of caries. The dentists telephoned a distant operator to be told which tooth to provide a Hall crown for and which tooth to manage with a standard restoration, and which to fit first, in order to reduce any bias in the trial. 132 children were enrolled in the trial and followed up every year clinically and with bitewing radiographs. The outcomes for the 124 patients seen at 2 years (8 patients failed to return for 2 year appointments) are shown in Figure 7.

A full report of the clinical trial can be found at <http://www.biomedcentral.com/1472-6831/7/18>.

## Clinical outcomes

As well as recording episodes of pain, the outcomes were broken into two categories;

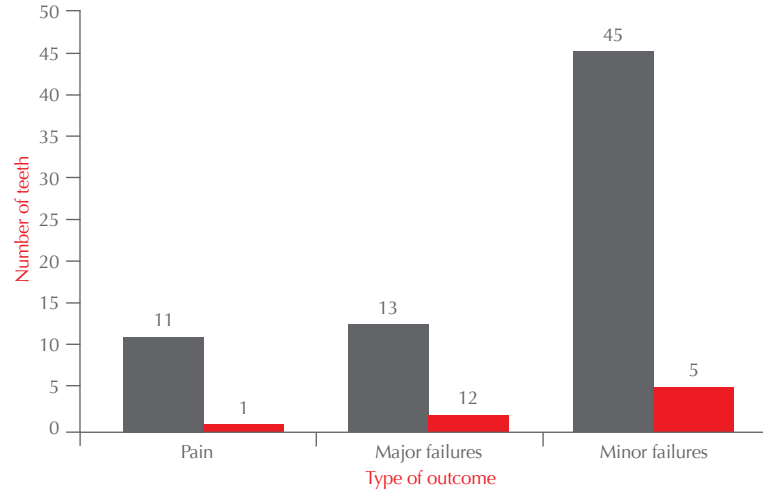
- **major failures**

This included the instances of irreversible pulpitis; where an abscess developed requiring pulpotomy or extraction; an inter-radicular radiolucency was seen on radiographs; or where the restoration was lost and tooth was now unrestorable

- **minor failures**

This category included failures which could be resolved by replacing a failed restoration; new or secondary caries; where the filling/crown had become worn, lost or was requiring another intervention to repair it, or where the restoration was lost but the tooth was restorable. It also included instances of reversible pulpitis which were treated simply by replacing the restoration and not requiring pulp therapy or an extraction to resolve.

**Figure 7.**  
2 year results for 124 teeth treated with the Hall Technique compared to 124 conventional restorations in a split mouth study with matched caries lesions prior to treatment

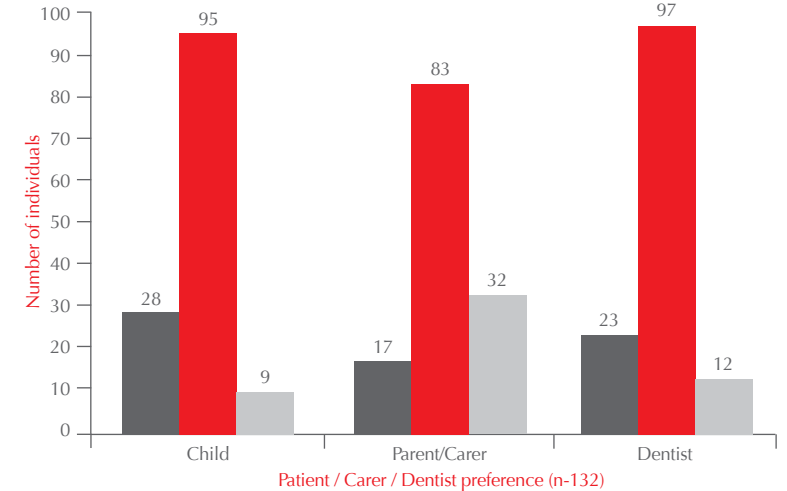


■ Conventional restorations  
■ Hall Technique

## And is the Hall Technique acceptable to children, their parents and dentists?

In the same clinical trial, the children, their parents/ carers and dentists stated whether they preferred the Hall or conventional restoration when both procedures were completed (see Figure 8).

**Figure 8.**  
Patient, carer and dentist preferences for Hall Technique or conventional restorations in a split mouth study for 132 children (264 teeth). Data from same study discussed above.



■ Conventional restorations  
■ Hall Technique  
■ No preference expressed

## Summary of evidence for the Hall Technique

This study showed the Hall Technique to be more effective than the restorations placed by the dentists, and an effective restoration in its own right. In addition, the study showed that the Hall Technique was preferred to conventional restorations by the majority of the children, their parents, and dentists.

# Case selection; using the Hall Technique in clinical practice

## Stage 1. Treatment planning for Hall crowns

### Some important information:

Hall crowns are not a universal answer to managing all carious primary molars. They are also not a “Lazarus restoration”, used to resurrect a tooth with a poor prognosis, when all conventional techniques have failed, or are impossible to provide. Instead, with proper case selection, the Hall Technique can be an effective management option for primary molar teeth affected by dental caries. The Hall Technique will not suit every dentist, every child, or every carious primary molar in that child. Other caries management methods are available, and should be considered, as appropriate. As with every treatment decision, clinicians should use their own clinical judgement in deciding which method is appropriate for their patient and within their own clinical capabilities to deliver, with consent being obtained from the patient, and parent, before delivering that treatment.

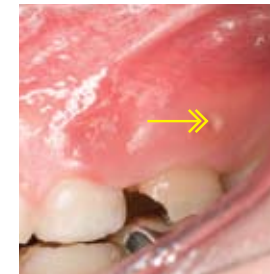## To begin with, exclude irreversible pulpal involvement...

A full history and clinical examination, including bitewing radiography, should be carried out. Vitality testing of primary molars with Ethyl Chloride is unreliable. Instead, dentists should use their clinical judgement in assessing the vitality, and viability, of a dental pulp, based on a thorough assessment, including:

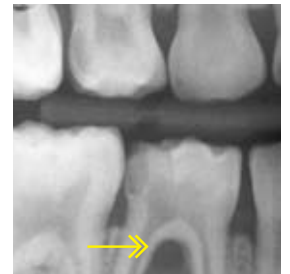- Clinical signs or symptoms of irreversible pulpitis, or dental abscess
- Radiographic signs or symptoms of dental abscess
- Non-physiological mobility, assessed by placing the points of a pair of tweezers in an occlusal fossa, and gently rocking the tooth bucco-lingually, and comparing with a healthy antimere
- An assessment of the extent and activity of a carious lesion, using clinical acumen to decide if there is likely to be pulpal involvement.

For example, the following are indicators of irreversible pulpal involvement, and would contraindicate the placement of a Hall crown without pulp therapy:

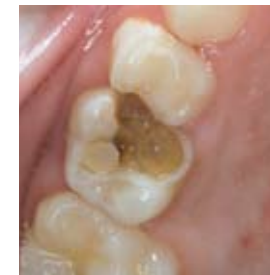**Figure 9.**  
There is a buccal sinus associated with this maxillary first primary molar (64).



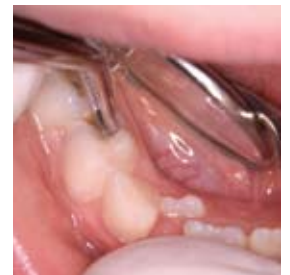**Figure 10.**  
This mandibular first primary molar (84) has inter-radicular pathology, indicative of a dental abscess.



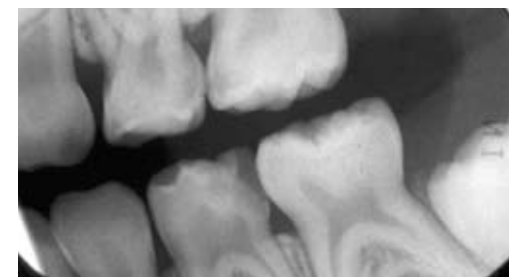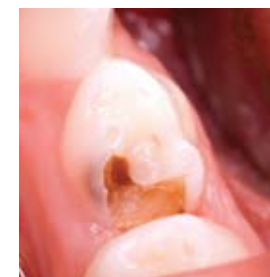**Figure 11.**  
This maxillary second primary molar (55) has an extensive mesio-occlusal cavity, that has been painful, keeping the child awake at night. This is indicative of an irreversible pulpitis, or even an abscess developing.



**Figure 12.**  
Here, a mandibular first primary molar (84) which has given occasional pain, but is currently symptomless, is found to have non-physiological mobility. This, with the DO cavity and history, indicates a dental abscess.

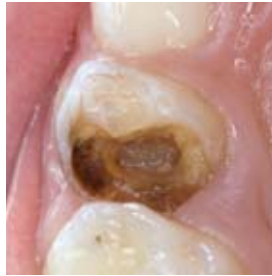

**Figure 13.**  
This mandibular first primary molar (84) has a large disto-occlusal cavity. Although symptomless, and with no inter-radicular pathology visible, there is no clear band of normal dentine between the caries and the pulp chamber. The pulp is almost certainly non-viable, and the tooth should have pulp therapy if a crown is to be placed.

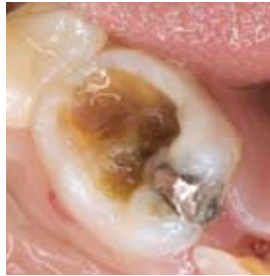



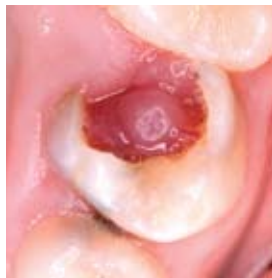**Figure 14.** This maxillary first primary molar (54) has a large multisurface cavity, with clinical exposure of a non-vital pulp chamber. Even in the absence of symptoms, this tooth should be extracted.



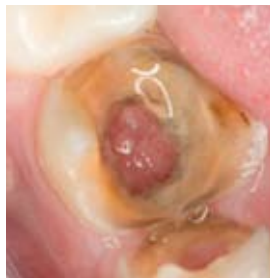**Figure 15.** This mandibular second primary molar (75) has a large occluso-lingual cavity which clearly involves the pulp chamber. Even in the absence of symptoms, the tooth should either be managed with pulp therapy or extraction.



**Figure 16.** This maxillary first primary molar (64) has a pulp polyp. The pulp, although exposed, is vital. In the absence of symptoms, and clinical and radiographic signs, of sepsis, it would not be unreasonable to simply monitor the tooth.



**Figure 17.** However, although this mandibular second primary molar (75) has a similar pulp polyp associated with the mesial root, there is clearly a sinus associated with a non-vital distal root, and the tooth should be managed by extraction.



Clinicians should continue to monitor all primary molars managed with Hall crowns for signs or symptoms of pulpal disease at every recall visit, just as they should for all carious primary teeth managed with conventional restorations.

**So, contra indications for fitting Hall crowns include:**

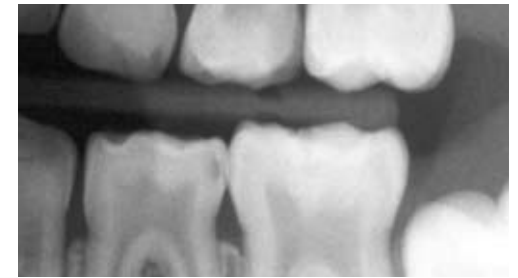
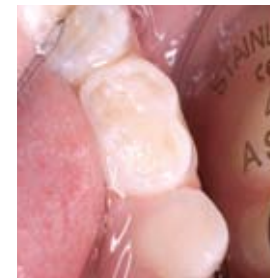- Irreversible pulpal involvement (discussed above)
- Insufficient sound tissue left to retain the crown
- Patient co-operation where the clinician cannot be confident that the crown can be fitted without endangering the patient's airway
- A patient at risk from bacterial endocarditis. In such situations, the tooth should be managed with a conventional restoration which would include complete caries removal
- Parent or child unhappy with aesthetics. This should become apparent though at the treatment planning stage when treatment options are being discussed and agreed with the parent and child.

## When can Hall crowns be a suitable management option for carious primary molars?

Here, the disadvantages of the aesthetics and the temporary bite opening will generally be counter balanced by the effectiveness of the restoration, for which there is a good evidence base.

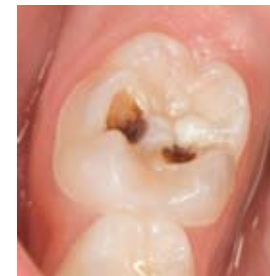This mandibular first primary molar (74) is appropriate for a Hall crown. The moderate distal lesion has been diagnosed reasonably early, by appropriate use of radiographs. The radiograph shows a band of sound dentine between the lesion and pulp, and no intra-radicular pathology.

**Figure 18.** Mandibular first primary molar, with early to moderate active caries on distal proximal surface; asymptomatic, and with no signs of pulpal pathology



Hall crowns can also be suitable for the moderately advanced Class I lesion where the extent of the cavity would make it difficult to obtain a good seal with an adhesive restorative material, following partial caries removal.

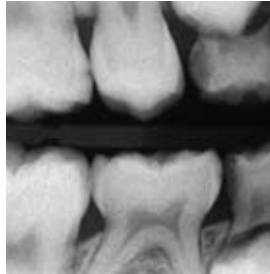**Figure 19.** Moderately advanced occlusal lesions on a mandibular second primary molar (85), where due to the extent of the cavities, obtaining a good coronal seal with a partial caries removal technique might be problematic



## When is there no need to fit Hall crowns?

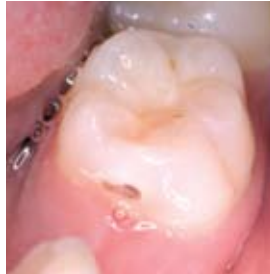**Figure 20.**

Both maxillary and mandibular first primary molars (54 & 84) although cavitated, are clearly going to be shed soon, so are unlikely to cause pain or sepsis before exfoliation.



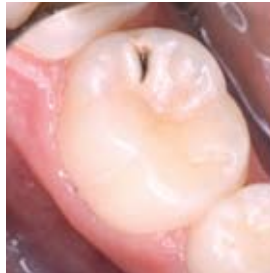**Figure 21.**

The mesial cavity on this mandibular second primary molar (75) is accessible, and can be managed with partial caries removal, sealing the cavity with an adhesive restorative material, avoiding both the aesthetics and bite propping of a Hall crown.



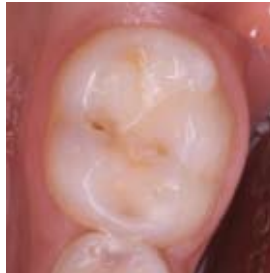**Figure 22.**

The cavitated occlusal lesion on this mandibular second primary molar (85) could be managed with partial caries removal, and sealing with an adhesive restorative material.



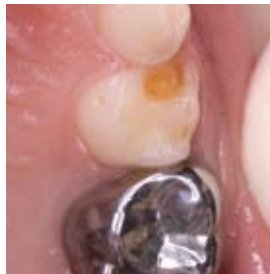**Figure 23.**

This mandibular second primary molar (75) has non-cavitated occlusal lesions which could be managed with a good quality, well maintained fissure sealant.



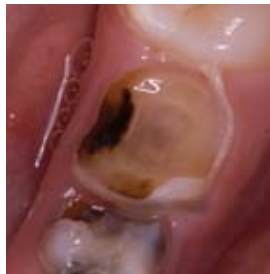**Figure 24.**

This mesial lesion on a maxillary first primary molar (64) is arrested. As the lesion is cleanable, there is no need for any management option other than prevention. However, this does depend on the carers/child continuing thorough cleaning and the tooth and lesion must be monitored for signs of the lesion progressing.



**Figure 25.**

There is insufficient tooth tissue on this mandibular second primary molar (75) to allow placement of any restoration. However, the caries is arrested, the pulp is shining pink through the floor of the cavity, and in the absence of symptoms, this could probably be managed with prevention, and monitoring.



## Summary

Summary of indications and contra-indications for the Hall Technique  
Indications and contra-indications for using the Hall Technique for managing primary molars with carious lesions assessed as at risk of causing pain/ sepsis before exfoliation

### Indications include teeth with:

- Proximal (Class II) lesions, cavitated or non-cavitated
- Occlusal (Class I) lesions, non-cavitated if the patient is unable to accept a fissure sealant, or conventional restoration
- Occlusal (Class I) lesions, cavitated if the patient is unable to accept partial caries removal technique, or a conventional restoration

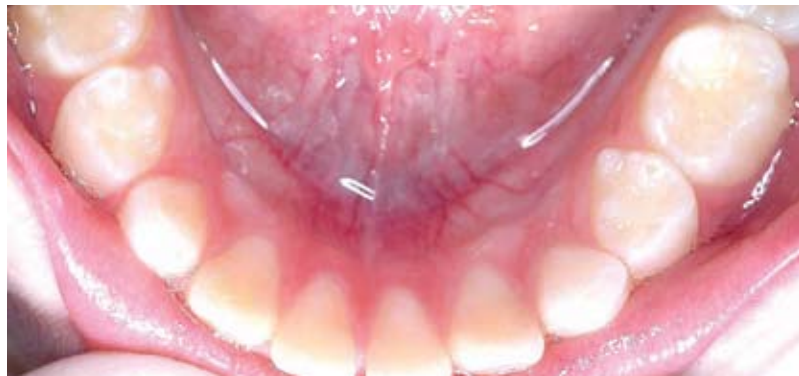### Contra-indications include teeth with:

- Signs or symptoms of irreversible pulpitis, or dental sepsis
- Clinical or radiographic signs of pulpal involvement, or periradicular pathology
- Crowns that are so broken down they would be considered unrestorable with conventional techniques

## Stage 2. Fitting Hall crowns; a practical guide

Although apparently very simple, the Hall Technique requires a confident, skilled approach from the operator if the crown is to be successfully fitted. In addition, there are some primary molars where, for a combination of reasons, even clinicians very familiar with the Hall Technique would have difficulty successfully fit a crown.

**Figure 26.**  
Mandibular first primary molars with an unusual morphology, which would complicate the fitting of PMCs with the Hall Technique should it prove necessary




Again, common to all clinical procedures, it is important that the clinician has a clear understanding of what to do to retrieve a situation which is not proceeding as planned, for example when a Hall crown is not seating properly onto a tooth or appears to be the wrong size or shape and will not fit correctly over the crown of the tooth. These issues are dealt with at the end of this section.

## The appointment for fitting the crown

Preparation is everything! The child and parent should be briefed on the procedure. Children should be shown a crown, and allowed to handle a spare one if felt beneficial. Young children sometimes respond to the idea of the crown being “a shiny helmet”, or “just like soldiers wear to protect their heads”, or “a precious, shiny, princess crown” or it being a “twinkle tooth”.

**Figure 3.**  
Text here



**It is important that the child knows that:**

- a) they will have to help, by biting the crown into place when asked to do so
- b) the cement will not taste nice and can be a bit like Salt & Vinegar crisps

# Fitting a Hall Crown

## Instruments to have ready

### Essential:

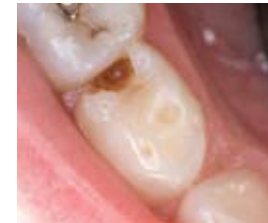- Mirror
- Straight probe
  - to remove separators, if used
- Excavator
  - to remove crown if necessary, and
  - useful for cement removal
- Flat plastic
  - to load crown with cement
- Cotton wool rolls
  - for child to bite down on and push crown over tooth, and
  - to wipe away cement

- Band forming pliers
  - can be useful for adjusting crowns, particularly where the primary molar has lost length mesio-distally due to caries
- Gauze to protect the airway and wipe off excess cement
- Elastoplast to secure the crown for airway protection

The practical aspects of fitting a Hall Crown can be broken down into the following seven stages:

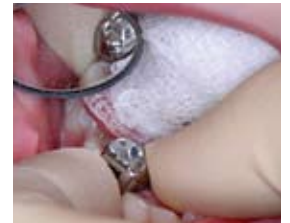### Step 1.

Assessing the tooth shape, contact points/ areas and the occlusion



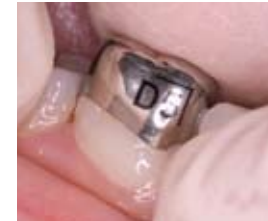### Step 2.

Protecting the airway



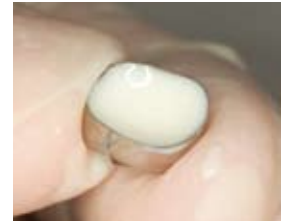### Step 3.

Sizing a crown



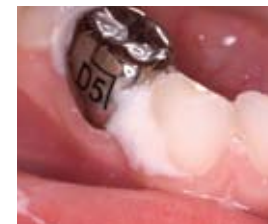### Step 4.

Loading the crown with cement



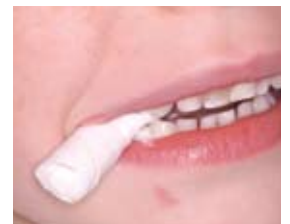### Step 5.

Fitting the crown, and first stage seating



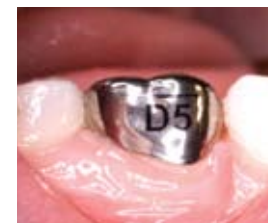
### Step 6.

Wipe the excess cement away, check fit, and second stage seating



### Step 7.

Final clearance of cement, check occlusion (adjusting crown if necessary) and discharge



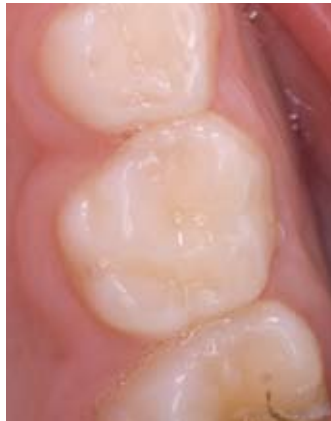

## Step 1 of 7: Assessing the tooth shape, contact points/ areas and the occlusion

### A) Tight contact points, and their management with separators

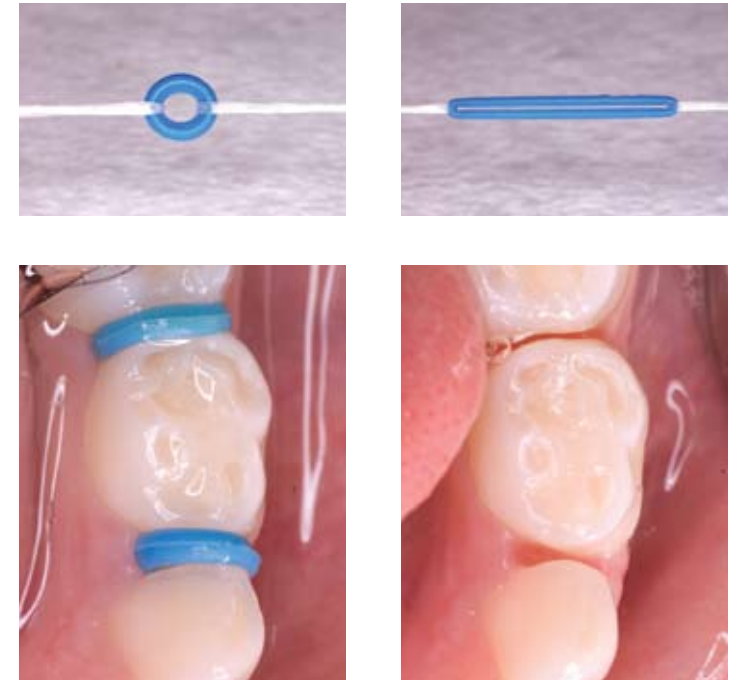
Hall crowns can often be fitted successfully to primary molars which are in contact with adjacent teeth, as there is some elasticity in the periodontal ligament which can absorb the displacement necessary to fit the crown. However, much depends on the willingness of the child to bite the crown into place, and on the shape of the contact point. Some teeth have very broad contact points, which can make fitting crowns difficult.

**Figure 27.**  
Broad contact point  
between a maxillary  
second primary molar  
(65) and the adjacent  
teeth



In such cases, placing orthodontic separators through the mesial and distal contacts can be useful when fitting crowns with the Hall Technique, although it does mean the patient will have to make a second visit. Two lengths of dental floss should be threaded through the separator. The separator should then be stretched taut, and “flossed” through the contact point briskly and firmly until the leading edge only is felt “popping through” the contact point. The floss should then be removed, and the patient seen 3 to 5 days later for removal of the separator.

**Figure 28.**  
The use of orthodontic  
separators to create  
space for fitting a Hall  
crown



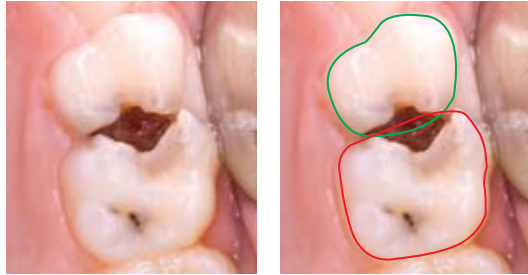
If the separator appears to have fallen out, the inter-proximal area of the gingiva should be inspected to check that the separator hasn't worked its way below the contact point. Separators are usually brightly coloured to facilitate this.

### B) Crown morphology and marginal ridge breakdown

Often where there is marginal ridge breakdown in one molar, there can be migration of the adjacent molar into the cavitated area. The picture below shows an example of this. If the missing tooth walls are imagined, they will be seen to overlap. This can make placing a Hall crown difficult without making some adjustments to the tooth itself or the crown.



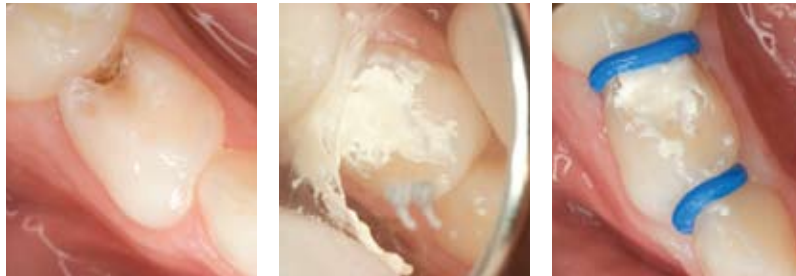
**Figure 29.** Maxillary first and second primary molars (64 & 65) with significant loss of mesio-distal dimension (in view of the extent of the dental caries, both of these teeth would require pulp therapy before fitting a PMC).



There are several different approaches to managing this problem if a crown cannot be fitted in the usual way:

- I. placement of a temporary restoration to rebuild the marginal ridge and allow a separator to be placed to make space for the crown to be fitted; or

**Figure 30.** Gentle excavation of a distal cavity on a mandibular first primary molar (74) is followed by placement of a celluloid matrix strip and a temporary dressing, allowing separators to be placed 10 minutes later




II. Adjusting the crown with band forming pliers

a)

b)

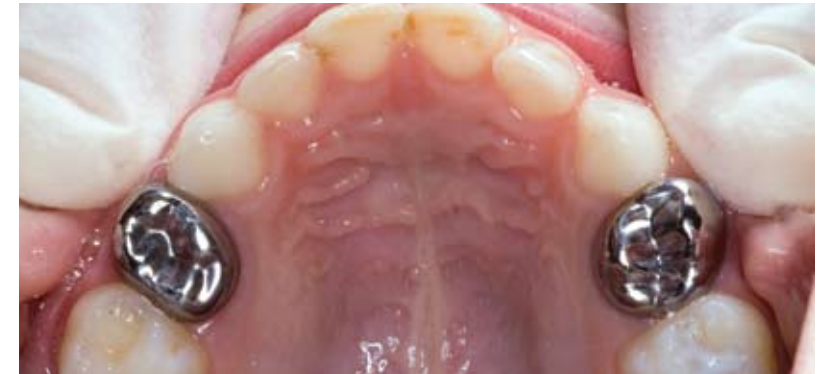c)

**Figure 31.** Band Forming pliers (a) being used to adjust the crown margins (b), and the effect of rotating them 180 degrees to “pinch in” a concavity to accommodate the intruding marginal ridge of an adjacent tooth (c).



III. Trying a different crown

**Figure 32.** Use of a mandibular molar crown to fit a maxillary first primary molar (54) with significant loss of mesio-distal width



- IV. Carrying out some tooth preparation; however, this will usually require the use of local anaesthesia

C) assessing the occlusion

Before fitting a Hall crown, check the following two points regarding the occlusion;

1. measure the anterior overbite (in order to assess the degree of propping of the bite following fitting of the crown)
2. check the buccal relationship of the tooth to be crowned with its opposing number (to ensure there is no laterally displacing contact following fitting of the crown)

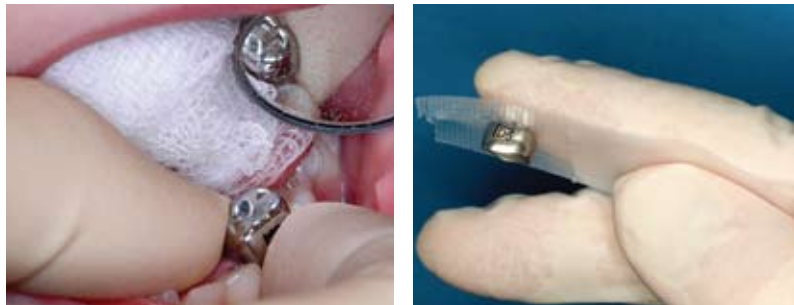## Step 2 of 7: Protecting the airway

It is also important, before the crown is placed, to ensure there will be no danger of the child inhaling or swallowing a loose crown (the same precautions as should be taken when fitting a conventional crown).

This is most easily done by sitting the child upright. However, for maxillary teeth, working with the child seated upright means that the optimum operator working position has to be compromised. For mandibular teeth, the operator can simply move to the front or side of the child.

There are additional ways of protecting the airway. A gauze swab square can be placed between the tongue and the tooth where the crown is to be fitted. It should extend to the palate and round the back of the mouth in front of the fauces. Alternatively, a piece of Micropore tape, doubled back on itself for part of its length, can be used to secure the crown.

Figure 33.  
Protecting the airway



If you are not confident about being able to control the crown at all stages until it is cemented, then do not use the technique.

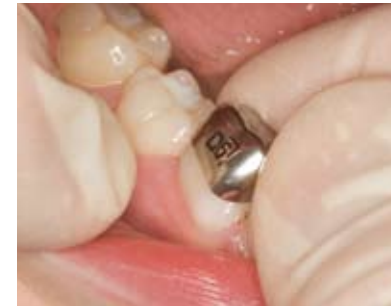## Step 3 of 7: Sizing a crown

Select different sizes of crowns until you find one which covers all the cusps, and approaches the contact points, with a slight feeling of “spring back”. You should aim to fit the smallest size of crown which will seat.

Be particularly careful not to fit an oversize crown to a second primary molar where the first permanent molar has still to erupt; this could increase the risk of first molar impaction later.

Do not be tempted to fully seat the crown through the contact points before cementation; they can be very difficult to remove!

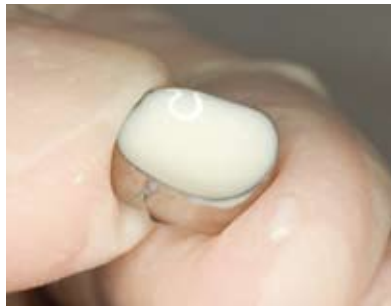Figure 34.  
Selecting the correct  
crown size



## Step 4 of 7: Loading the crown with cement

- Following try in, dry the inside of the crown, using the end of a cotton wool roll
- Load the crown generously (it should be at least two thirds full) with a glass ionomer luting cement. Take care fill the crown from the base upwards and ensure that there is cement around all the walls. Be careful to avoid air blows and voids

Figure 35.  
Loading the crown  
with cement



## Step 5 of 7: Fitting the crown, and first stage seating

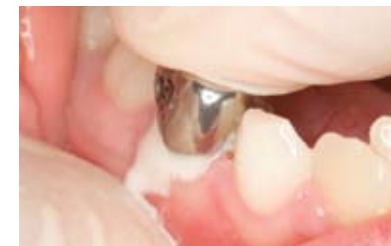Place the crown over the tooth. Fully seating the crown is a key stage! It is not always easy, and requires a committed, positive approach from the clinician. The child needs to have complete confidence that you know exactly what you are doing; that what you are asking them to do is perfectly reasonable, and that it will not be uncomfortable. Remember that our research found that, surprisingly, most children do not find the procedure painful, and prefer it to conventional fillings. There are two main methods of seating the crowns:

- a) the clinician seats the crown by finger pressure
- b) the child seats the crown by biting on it

## A combination of these two methods may be necessary or preferred.

- Some clinicians will seat the crown with firm finger pressure alone. For mandibular teeth, a useful method is to place your thumb on the occlusal surface of the crown, with the four fingers of your hand placed under the border of the mandible to spread the force as you apply firm pressure with your thumb. For maxillary teeth, the child's head may be supported by the back of the dental chair, or sometimes by placing your other forearm gently on the top of their head to balance the force applied when fitting the crown.
- Often, the child will seat the crown themselves by biting it into place. It can be useful to verbally encourage the child to apply the necessary pressure ("Bite hard, like a Tiger! Grrrrr...!"), and to rehearse this before fitting the crown. If using this method, be aware that some children's resolve might falter a little, leaving the crown not fully seated. Here, a timely "That was great! Now let me just check it for you! Ooh, well done, and I'll just give it a little squeeze..., Excellent!" can help.
- Some clinicians partially seat the crown until it engages with the contact points, allowing the finger to be removed without risk of the crown falling off, and the child then being encouraged to bite the crown into place. It must be remembered that your working time with glass ionomer cements is limited, and whatever method is used, you must work smoothly and efficiently. Crowns cannot be seated, no matter how hard either you or the child tries, if the cement has started to thicken.
- It is crucial that the orientation of the crown relative to the tooth is checked either during, or immediately after, seating the crown. If it does not appear to be going on straight, then you must give the crown some physical encouragement to go in the correct direction. If it is not possible to seat it then it should be removed before the cement sets.

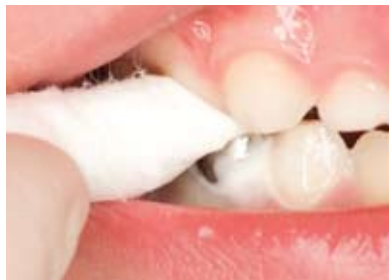Figure 36.  
Fitting the crown, and  
first stage seating



## Step 6 of 7: Wipe the excess cement away, check fit and second stage seating

- As soon as the crown is fitted, the child should be asked to open to allow the crown position to be checked and excess glass ionomer can be wiped away.
  - With either technique, excess cement will be extruded from the crown margins, and the taste of this can upset children. In anticipation of this, as soon as the crown is seated, the child should be asked to open their mouth, and the cement wiped off with a cotton wool roll held ready for this purpose. If a gauze swab has been used to protect the airway, this can be used to wipe away excess cement from the lingual/ palatal side of the tooth as it is being removed.
  - If it is obvious that the crown has not seated, and finger pressure fails to seat it, then it should be removed immediately using the large excavator which you should have placed within easy reach. If you do not work swiftly, you may have to section the crown to remove it.
  - If the crown is fitting satisfactorily, the child should be asked to bite firmly on the crown for 2-3 minutes, or the crown should be held down with firm finger pressure as an alternative. Often the crown will seat a little further, expressing more cement. This is possibly due to accommodation to the displacing pressure by the adjacent teeth.
  - It is important to maintain firm pressure on the crown until the cement sets, as the crowns can spring back a short way, sucking back the cement from the margins and potentially causing breaches in the seal.

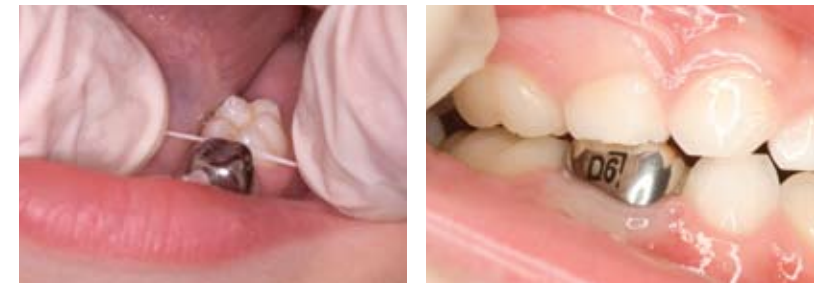Figure 37.  
Second stage seating



## Step 7 of 7: Final clearance of cement, check occlusion and discharge

- Remove excess cement, flossing between the contacts
- Blanching usually disappears within minutes. The occlusal discrepancy (here it is minimal) should resolve in a few weeks.
- Measure the degree of bite opening and record in the notes. If excessive, then consider either removing the occlusal part of the crown with a high speed handpiece, so that it becomes similar to an orthodontic band, or removing the entire crown.
- Check the buccal relationship of the crowned tooth with its opposing number. If there is a displacing contact, resulting in a cross bite, then manage as for excessive bite propping
- Advise the parent and child that the child will probably notice the crown as being high in the bite, but that this will no longer bother them by the following day. If there are any problems, then the child should be brought back to the surgery.
- Give the child a sticker.

Figure 38.  
Final clearance  
of cement, check  
occlusion and  
discharge



Finally, the pulpal health of a primary molar fitted with a Hall crown should be monitored at subsequent recall visits just as for any other carious primary tooth. If irreversible pulpal disease is diagnosed, then either a pulp therapy should be provided, or the tooth should be extracted.

## Some additional notes

- 1) Hall crowns should **not** be fitted to opposing (occluding) teeth at the same appointment. The occlusion should have re-established, with bilateral contacts, before opposing crowns are fitted. However, if a primary molar on either side of the same arch needs a Hall crown (or diagonally opposite teeth in different arches, i.e. a maxillary left primary molar and a mandibular right primary molar), then these **can** (and ideally **should**) be fitted at the same appointment, as the patient will have two crowns fitted with just one episode of bite propping.
- 2) In the authors' experience, it is usually not possible to fit a crown using the Hall Technique to both primary molars in the same quadrant at the same appointment; adjacent primary molars requiring Hall crowns should have them fitted at separate appointments.
- 3) The crowns used in the research presented here were Stainless Steel Primary Molar Crowns, cemented with AquaCem, both from 3M/ESPE. Any adjustment of the crowns was minimal, and was limited to re-moulding the crown margins in some cases with orthodontic pliers. The margins were not trimmed on any crowns.
- 4) Crowns will try to follow the path of least resistance, and so may tilt towards the "easier" of the contacts, making it almost impossible then to ease the crown through the tight contact. Concentrate on seating the crown through the tight contact, and the easy one should take care of itself.
- 5) If the crown does not seat sufficiently, then remove it using the excavator before the cement sets. If the cement has set, a high speed handpiece can be used to section the crown through the buccal and occlusal surface, following which it can easily be peeled off.
- 6) Patients and parents should be reassured that the child will be used to the feeling within 24 hours. It is the authors' experience that analgesia is not required. The occlusion tends to adjust to give even contact on both sides within weeks.
- 7) If fitting crowns to second primary molars, particularly in the maxilla, before the first permanent molars are erupted, keep an eye out for the first permanent molars becoming impacted against the crown margin as they erupt. This can occur even if crowns haven't been fitted, and there is no evidence from the authors' clinical trial that there is an increased risk of this. Nevertheless, if it does occur, it can often be managed with orthodontic separators if detected early.
- 8) If a primary molar fitted with Hall crown requires a pulp therapy, then this can be carried out through the crown without needing to remove it.
- 9) The Hall Technique is not a "fit and forget" technique. Patients should be reviewed on a normal recall schedule, with radiographic examination in line with current recommendations, and the Hall Technique should be used in conjunction with a full preventive programme.
- 10) Occasionally a crown will wear through occlusally. If this occurs, it can be repaired with composite material.



## Acknowledgements

The authors would like to thank The Chief Scientists Office of the Scottish Government, and 3M/ESPE for funding the clinical trial of the Hall Technique, and 3M/ESPE for funding the printing of this guide. The authors would also like to thank Mr Simon Scott, of the Department of Medical Illustration, University of Dundee, for the photography.

## Final note

The field of cariology and together with it, the management of caries in the primary dentition, is rapidly changing.

Please let us know of your thoughts and comments regarding the Hall Technique, or on any other matter relating to management of the carious primary dentition.

We also welcome feedback on this manual and how it might be improved.



**Dafydd Evans**  
d.j.p.evans@dundee.ac.uk



**Nicola Innes**  
n.p.innes@dundee.ac.uk

Further copies of this manual can be obtained free of charge by download from the Scottish Dental website (<http://www.scottishdental.org/>) at <http://www.scottishdental.org/resources/HallTechnique.htm>

## Bibliography and further information

### “Sealing in” caries

1. Ricketts, D.N., Kidd, E.A., Innes, N. and Clarkson, J., 2006. Complete or ultraconservative removal of decayed tissue in unfilled teeth. *Cochrane database of systematic reviews* (Online), 3.
2. Marsh PD. Dental plaque as a microbial biofilm. *Caries Research* 2004; 38(3): 204-11.
3. Riberio, C.C.C., Baratieri, L.N., Perdigao, J., Baratieri, N.M.M., Ritter, A.V., 1999 A clinical and radiographic, and scanning electron microscopic evaluation of adhesive restorations on carious dentin in primary teeth. *Quintessence International* 1999; 30(9):591-9.
4. Paddick, J.S., Brailsford, S.R., Kidd, E.A.M. and Beighton, D., 2005. Phenotypic and genotypic selection of microbiota surviving under dental restorations. *Applied and Environmental Microbiology*, 71(5), pp. 2467-2472.
5. Going RE, Loesche WJ, Grainger DA, Syed SA. The viability of microorganisms in carious lesions five years after covering with a fissure sealant. *Journal of the American Dental Association*. 1978; 97: 455-62.
6. Handelman ,S.L., Leverett, D.H., Espeland, M.A. and Curzon, J.A., 1986. Clinical radiographic evaluation of sealed carious and sound tooth surfaces. *The Journal of the American Dental Association*,113(5), pp. 751-754.

### The Hall Technique

7. Innes N.P., Evans D.J., Stirrups D.R. 2007. The Hall Technique; A randomized controlled clinical trial of a novel method of managing carious primary molars in general dental practice: Acceptability of the technique and outcomes at 23 months. *BMC Oral Health*; 7. <http://www.biomedcentral.com/1472-6831/7/18>
8. Innes, N.P.T., Stirrups, D.R., Evans, D.J.P., Hall, N. and Leggate, M., 2006. A novel technique using preformed metal crowns for managing carious primary molars in general practice - A retrospective analysis. *British Dental Journal*, 200(8), pp. 451-454.
9. Innes N.P.T., Evans D.J.P., Stirrups D.R., 2006. Clinical pulpal responses to sealing caries into primary molars: 2 year results of an RCT. *Caries Research*, 40: 327.
10. Innes NPT, Evans DJP, Hall N., 2009. The Hall Technique for managing carious primary molars. *Dental Update*, 36:472-478.
11. Evans D.J.P., Innes N.P.T., Stirrups D.R., 2006. Longevity of Hall Technique crowns compared with conventional restoration for primary molars; 2 year results. *Caries Research*; 40: 327.
12. Evans, D.J.P., Southwick, C.A.P., Foley, J.I., Innes, N.P., Pavitt, S.H. , and Hall, N., 2000. The Hall Technique: a pilot trial of a novel use of preformed metal crowns for managing carious primary teeth. *Tuith* <http://www.dundee.ac.uk/tuith/Articles/rt03.htm>



Further copies of this manual can be obtained free of charge by download from the Scottish Dental website (<http://www.scottishdental.org/>) at <http://www.scottishdental.org/resources/HallTechnique.htm>

University of Dundee

## The Hall Technique

A minimal intervention and child friendly approach to managing the carious primary molar

### A Users Manual

Text copyright Nicola Innes & Dafydd Evans  
Illustrations copyright Dafydd Evans & Amy McKay

3M ESPE have sponsored the clinical study on the Hall Technique but any treatment decision involving the use of the Hall Technique remains wholly the responsibility of the treating dentist.